


PATIENT

Gus Lieb

SPECIES

Feline

BREED

DSH

SEX

Male Neutered

AGE

14.7 years

WEIGHT

9.6lbs; 4.4kgs

INTERPRETED BY

 Maggie Machen Lamy,
 DVM, DACVIM
 (Cardiology)

IMAGING PERFORMED BY

 Loetitia St-Jacques,
 LVT/RVT

HOSPITAL NAME

 Mount Rose Animal
 Hospital

REFERRING VET

Dr. Lopez

INVOICE

24048

DATE

5/5/22

PRESENTING CLINICAL SIGNS

History: LAD on ECG. No murmur ausculted.

ECHOCARDIOGRAM FINDINGS

2D, m-mode, color flow and doppler imaging is available. The left ventricular wall is normal in dimension. There is a mildly remodeled endocardium consistent with fibrosis. The papillary muscles are mildly remodeled. The left atrium is normal in size. The right atrium is normal in size. The right ventricle appears normal. The mitral valve is normal in structure and mobility. Trace TR. Normal velocity. Blood flow through both the LVOT and RVOT is normal in velocity. No pleural or pericardial effusion seen. No obvious cardiac tumors.

CARDIAC CHART

FELINE CARDIAC PARAMETERS	BODY WEIGHT (kg)	HR (BPM)	IVSd (cm) (Moise, Pipers)	LVIDd (cm) (Moise, Pipers)	LVWd (cm) (Moise, Pipers)	FS (%)	EF (%)
NORMAL PARAMETER	-----	150-240	0.35-0.55	<2 (mean 1.5)	3.5-0.55	35-67	80-100
PATIENT	4.4	NM	0.42	1.3	0.37	58	90
FELINE CARDIAC PARAMETERS	LA/AO (Boon)	LA/AO HEART BASE (Swe) (Abbott)	LA 2D short axis Base view (cm) (Abbott)		LVOT VEL (m/s)	RVOT VEL (m/s)	E max (m/s)
NORMAL	<1.5	<1.3	<1.2		<1.6	<1.3	<0.9
PATIENT	NM	1.3	1.18		1.0	0.8	NM

*Note: All measurements based upon multi-modal images and methods. An average value is reported.

Adapted from June Boon, Veterinary Echocardiography, 1998

Abbott J & MacLean H JVIM 2006;20: 111-119, Moise et al. Am J Vet Res 47:1476, 1986. Pipers et al. Am J Vet Res 40:882, 1979.

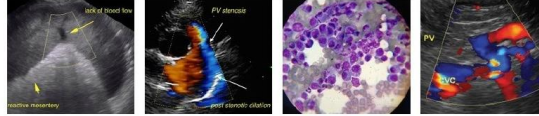
INTERPRETATION OF THE FINDINGS & FURTHER RECOMMENDATIONS

Overtly normal cardiac structure and function. The LV wall thickness is normal and there is no evidence of elevated left atrial pressure. There is mild remodeling and fibrosis of the left ventricular wall, which is considered a normal variant. Follow up is advised. No additional issues are identified.

A left axis deviation in cats can be indicative of structural disease or may be a normal variant. Fortunately given these findings, this is likely idiopathic/benign in origin in this case.

Given these findings, no medications are indicated. No cardiac contraindication for general anesthesia.

Recommend recheck echocardiogram in 1 year to screen for any progressive changes, sooner should a murmur, gallop or clinical signs of cardiac compromise be noted in the future.



PATIENT

Gus Lieb

SPECIES

Feline

BREED

DSH

SEX

Male Neutered

AGE

14.7 years

WEIGHT

9.6lbs; 4.4kgs

INTERPRETED BY

Maggie Machen Lamy,
DVM, DACVIM
(Cardiology)

IMAGING PERFORMED BY

Loetitia St-Jacques,
LVT/RVT

HOSPITAL NAME

Mount Rose Animal
Hospital

REFERRING VET

Dr. Lopez

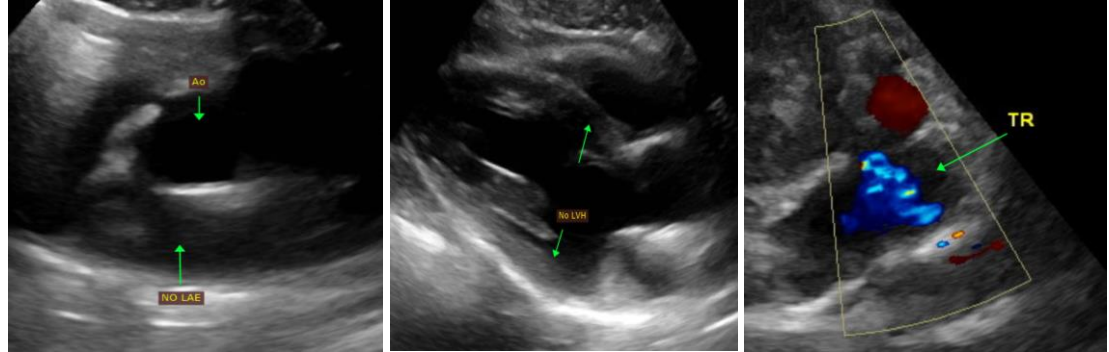
INVOICE

24048

DATE

5/5/22

IMAGES



The information and recommendations provided are based on the images presented by the referring veterinarian. No evaluation can be communicated regarding pathology that was not visible in the image/video clips provided.

Thank you for this referral. This report was generated using transcription software, and minor dictation errors may be present. If the clinical or image interpretation does not parallel your findings or if I can be of any further assistance, please contact me.

Maggie Machen Lamy, DVM
Diplomate of the American College of Veterinary Internal Medicine (Cardiology)
info@sonopath.com